



PATIENT

Coriander Gultinan

PRESENTING CLINICAL SIGNS

Abdominal mass effect 5/1 annual exam. Current Medications: Gabapentin 800mg
Abnormal PE/Chem/CBC/UA Results: Pending

SPECIES

Canine

ULTRASONOGRAPHIC EXAMINATION OF THE ABDOMEN

Urinary System

BREED

Golden Retriever

The urinary bladder, trigone, cystourethral junction, and visible pelvic urethra exhibited normal thickness and tone. Anechoic urine was present in the lumen with no evidence of urine/lumen sediment, mineral, or calculi. The ureteral papillae were normal. The ureters were not visible which is normal. No evidence of inflammatory or neoplastic changes was noted.

SEX

FS

Normal size and margination were present in the kidneys. A normal 1:3 cortex / medulla ratio and normal corticomedullary definition were maintained. The echogenicity of the cortex was similar to or slightly less than normal liver parenchyma while the medulla echogenicity was hypoechoic to the cortex with no evidence of pelvic dilation. The left kidney measured 6.5 cm in length. The right kidney measured 6.7 cm in length.

AGE

8yr

The area of the aortic trifurcation was free of pathology.

Adrenal Glands

WEIGHT

74.5lb

The left adrenal gland was uniform in size and contour with a uniformly hypoechoic parenchyma. The left adrenal gland measured 0.75 cm width at the caudal pole. The right adrenal gland was uniform in size and contour with a uniformly hypoechoic parenchyma. The right adrenal gland measured 0.73 cm width at the caudal pole.

INTERPRETED BY

R. McKenzie Daniel,
DVM, DABVP
(Canine and Feline)

Spleen

A mass involving the spleen with secondary asymmetrical capsule expansion and disruption was present and measured 6-7 cm diameter. The parenchyma of the mass was heterogeneous to mixed echogenic with areas of cavitation. Concurrent, separate mildly expansive non-homogenous splenic nodules were present, an example measured 1.6 cm in diameter. The non-affected spleen exhibited primarily finely textured and homogenous parenchyma which was hyperechoic to the liver and renal cortical parenchyma. The splenic vasculature at the hilus was normal in volume with no evidence of congestion or thrombosis. Regional omental inflammation was present around the mass.

IMAGING PERFORMED BY

Shari Reffi CVT

Liver/Gallbladder

HOSPITAL NAME

Chester Animal Hospital

The liver was subjectively normal in size, structure, and contour. The liver parenchyma was uniform and hypoechoic to the spleen with a mild coarse echotexture. Normal vascular volume. The hepatic and portal vasculature were normal in appearance without signs of congestion. The gallbladder was non-distended in size with thin walls and primarily anechoic luminal content. The cystic and common bile ducts were normal.

REFERRING VET

Dr Migliacco

Gastrointestinal

INVOICE

24801

The stomach presented intact wall layering with a normal wall layer ratio. The lumen of the stomach was empty with no signs of ileus, obstruction or foreign material.

DATE

05/12/2026



PATIENT	The small intestine presented intact wall layering with 1:3 muscularis/mucosa ratio. The lumen of the small intestine was empty with no signs of mechanical/metabolic ileus, obstruction or foreign material.
Coriander Guiltinan	Normal visible colon wall layers were present with apparent formed feces in lumen.
SPECIES	Pancreas
Canine	The parenchyma of the left limb, body and right limb of the pancreas presented isoechoic to the adjacent omental fat. A normal curvilinear capsule contour of the pancreas was present. The visible pancreatic duct was normal. No signs of active inflammation or neoplastic disease was evident.
BREED	Free Abdomen
Golden Retriever	Mild perisplenic hyperechoic omentum.
SEX	Scant perisplenic effusion.
FS	No obvious visualized significant or swollen mesenteric lymphadenopathy.
AGE	Rapid view of the heart revealed no evidence of pericardial masses or effusion in the visible window.
8yr	ULTRASONOGRAPHIC FINDINGS
WEIGHT	Primary
74.5lb	<ul style="list-style-type: none"> • Splenic mass with concurrent non-homogenous splenic nodules • Mild perisplenic hyperechoic omentum and minor effusion • Sonographically unremarkable liver • Sonographically normal right atrium on brief subjective echocardiogram
INTERPRETED BY	INTERPRETATION OF THE FINDINGS & FURTHER RECOMMENDATIONS
R. McKenzie Daniel, DVM, DABVP (Canine and Feline)	Although histopathology is required for definitive diagnosis, the splenic mass is most suggestive of neoplasia such as sarcoma or other. Benign pathologies are possible yet considered less likely.
IMAGING PERFORMED BY	Obvious sonographic evidence of major organ or cardiac metastasis was not overtly evident. Non sonographically evident metastasis / micrometastasis cannot be definitively excluded. If no pathology on thoracic radiographs, splenectomy with gross inspection of the perisplenic omentum and abdominal cavity is warranted.
Shari Reffi CVT	
HOSPITAL NAME	
Chester Animal Hospital	
REFERRING VET	
Dr Migliacco	
INVOICE	
24801	
DATE	
05/12/2026	



PATIENT
 Coriander Guiltinan

SPECIES
 Canine

BREED
 Golden Retriever

SEX
 FS

AGE
 8yr

WEIGHT
 74.5lb

INTERPRETED BY
 R. McKenzie Daniel,
 DVM, DABVP
 (Canine and Feline)

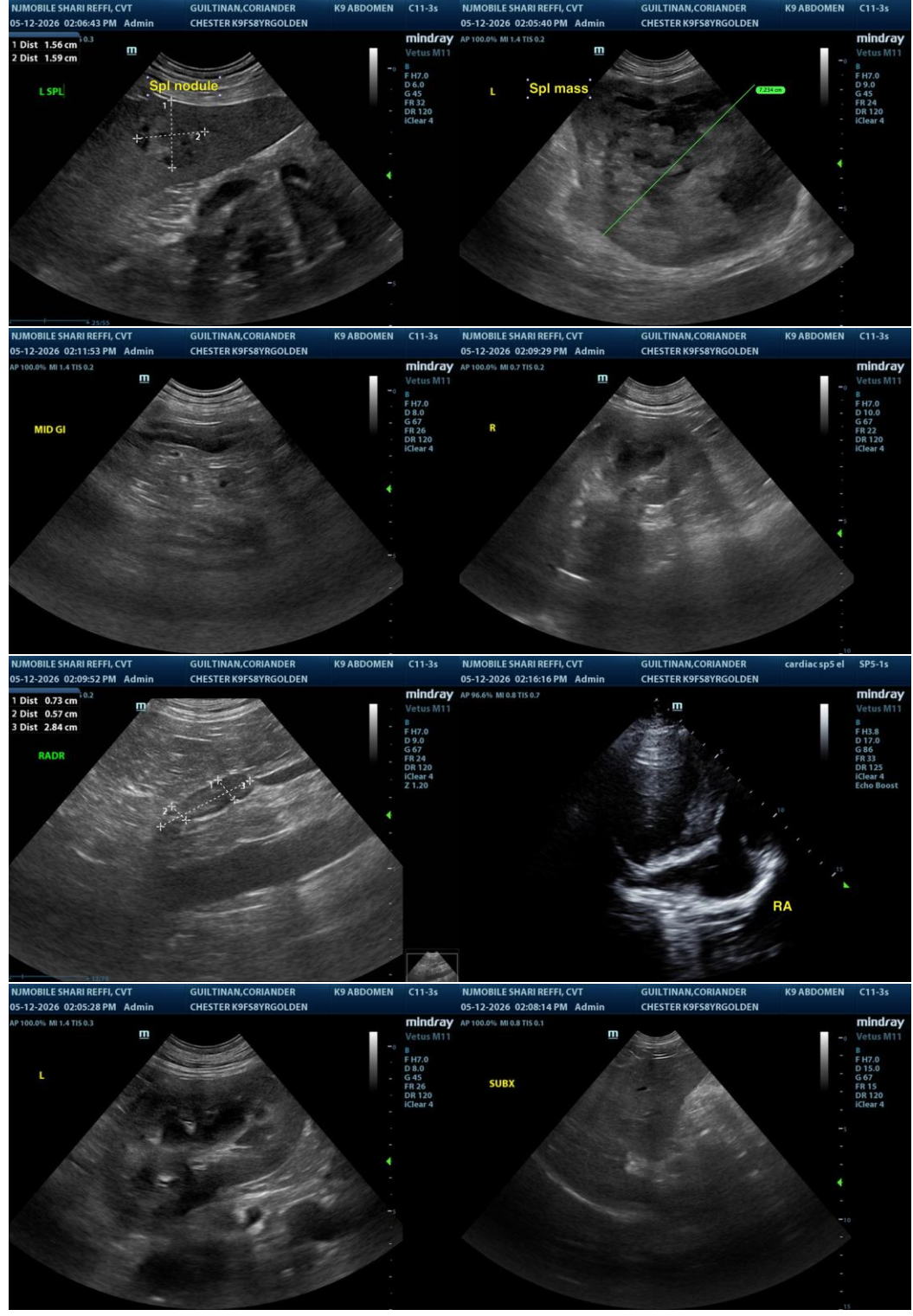
IMAGING PERFORMED BY
 Shari Reffi CVT

HOSPITAL NAME
 Chester Animal
 Hospital

REFERRING VET
 Dr Migliacco

INVOICE
 24801

DATE
 05/12/2026





PATIENT
 Coriander Guiltinan

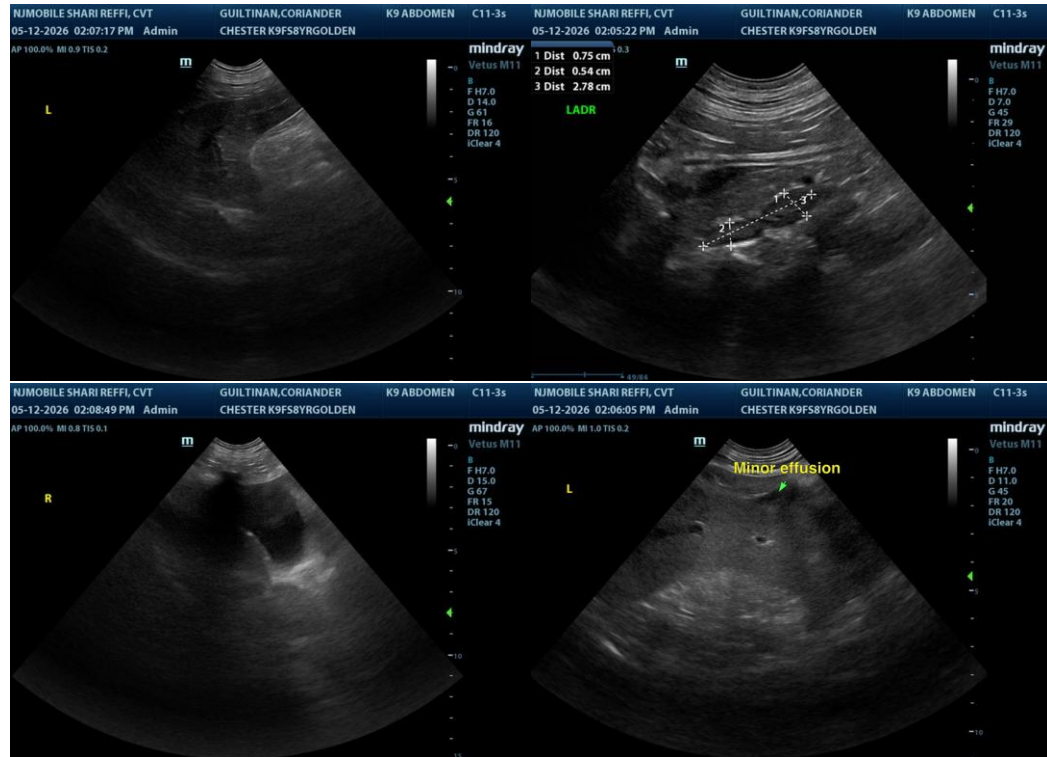
SPECIES
 Canine

BREED
 Golden Retriever

SEX
 FS

AGE
 8yr

WEIGHT
 74.5lb



The information and recommendations provided are based on the images presented by the referring veterinarian/sonographer. No evaluation can be communicated regarding pathology that was not visible in the image/video clips provided.

INTERPRETED BY
 R. McKenzie Daniel,
 DVM, DABVP
 (Canine and Feline)

Thank you for this referral. If the clinical or image interpretation does not parallel your findings or if I can be of any further assistance, please contact me.

IMAGING PERFORMED BY

R. McKenzie Daniel, DVM, DABVP (Canine/Feline Practice)
info@sonopath.com

Shari Reffi CVT

HOSPITAL NAME

Chester Animal Hospital

REFERRING VET

Dr Migliacco

INVOICE
 24801

DATE
 05/12/2026